


ERYTHROPLAKIA OF THE ORAL CAVITY: a severe potentially malignant lesion.



Clinical case study



A CLINICAL CASE PRESENTATION

Dr. Silvio Abati, M.D., D.M.D

Professor of Oral Diseases

Medical School and Dental School

University Vita-Salute San Raffaele - Milano

Introduction

Despite recent advances in oral cancer treatment, the survival rates of affected patients are still low and do not exceed 60% globally five years after diagnosis.

The disease aggressiveness, the anatomical complexity of oral sites and the stage of the disease at the time of diagnosis are the main reasons for the high mortality of these malignant tumors, the morbidity associated with therapies and the deterioration of the patient's residual quality of life.

Over 85% of oral malignant tumors originate from the epithelium of the oral mucosa as oral squamous cell carcinomas (OSCC).

They are in most cases preceded by diseases and lesions of the mucosa which are not still malignant tumors but that can transform and develop as cancers.

Patients with early-stage oral cancers often present only vague symptoms with minimal oral mucosal lesions. Early identification of signs, symptoms and lesions related to oral premalignant diseases or cancers can reduce the mortality and the morbidity.

PMOLs or potentially malignant oral lesions, previously known as oral precancerous lesions, are areas of genetically altered tissues more likely than normal oral mucosa to transform in cancers. The most frequent PMOLs are leukoplakia, erythroplakia, lichen planus and submucosal fibrosis.

Oral erythroplakia is a red plaque or patch of the oral mucosa that cannot be clinically diagnosed as any other known disease or condition.

The reported prevalence varies between 0.02% and 0.2%. Oral erythroplakia is the PMOL with the highest rate of malignant transformation and in over 50% of cases evidentiates the presence of malignant tissues with histopathology.

Oral erythroplakia is often asymptomatic and sometimes difficult to find with the clinical examination.

If a persistent red area of the oral mucosa is still observed after 14 days from the first visit, a diagnostic biopsy with histopathology is always required to reveal the characteristics of the pathological tissue and the possible presence of dysplasia or malignant tissue.

In recent decades, devices have been introduced into clinical practice that allow the visual inspection of the so-called "autofluorescence" (OFI) of the oral mucosa during the clinical examination of the oral cavity.

Devices for the detection of the autofluorescence of the oral mucosa can be used and useful to improve the identification of areas of inflammation or premalignancy or cancer, in order to improve the selection of areas where to perform the diagnostic biopsy and/or to control the progression and results of surgical and medical care of the affected patient.

Clinical case presentation

The clinical case of a 62-year-old man suffering from erythroplakia of the oral cavity is described, where the incisional biopsy examination histologically showed severe dysplasia while the histopathology of the subsequent surgical removal demonstrated oral squamous cell carcinoma.

Patient G.B. came in the outpatient unit of Oral Pathology and Medicine. He was sent by his dentist and dental hygienist because of the presence of an area of redness in the oral cavity.

The patient reported that he was neither a smoker, had never smoked, moderately consumed low-grade alcohol at meals and was not suffering from systemic diseases, except for high blood pressure treated with an appropriate ACE-inhibitor drug.

The patient also reported that the area of abnormal redness had been present for several months, and caused a slight burning when acidic or spicy foods came into contact.

The visual clinical examination showed a polygonal lesion of red color of about 2x2 cm (Figure 1) between the upper left retromolar trigone, the hard palate and soft palate. The abnormal reddish area showed small areas of whitish color (erythroleukoplakia) towards the upper limit.

The palpation of the lesion demonstrated tissue of an increased consistency with a velvety papillary surface. Firm palpation caused a localized slight bleeding.

The subsequent oral inspection with the OFI - optical fluorescence inspection device (Goccles® by Pierrel) device showed a dark color from irregular loss of autofluorescence, extended throughout the entire surface of the abnormal area (Figure 2).

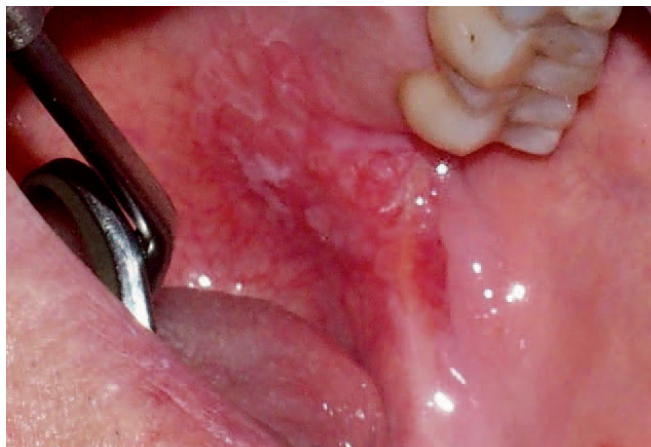

Fig. 1.

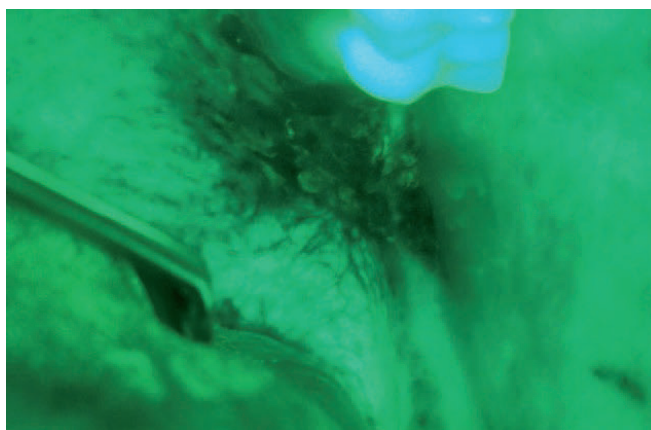


Fig. 2.

Due to persistence greater than 14 days and the clinical appearance of the lesion, with the agreement of the patient, it was decided to immediately proceed with an incisional biopsy from the area identified and delimited by OFI visual examination.

After local infiltration of oral articaine anaesthetic 40mg/ml with vasoconstrictor 10mcg/ml, a small piece of pathologic tissue was taken by single-use punch scalpel 6mm dia; the bioptic specimen has been oriented on special paper, placed into the bottle with 10% buffered formalin fixative pH 7.0 and sent to the unit of pathology with the case description on a special form.

In view of the oncological hypothesis, local hemostasis was obtained with compression without suturing, to avoid the deep transport of malignant cells.

The patient was discharged with appropriate dietary instructions (cold foods and drinks for the day, and no traumatic foods for a week) and recommendations in case of bleeding from the wound.

Chlorhexidine gel 0,5% was also prescribed to be applied twice a day for seven days and clinical control in the eighth day.

Histopathological examination of the biopsy showed “keratosis with severe dysplasia” and the patient was sent to the division of Otolaryngology for transoral surgical removal of the entire lesion, to be performed with CO2 laser in general anesthesia.

Histopathological examination of the complete lesion removed showed “the presence of a G2 early-stage squamous cell carcinoma with minimal infiltration of the chorion in the area of keratosis with severe dysplasia, with bottom and peripheral borders free from disease”.

The biannual clinical and imaging follow-up performed showed persistent clinical healing with any sign of disease recurrence.

Conclusion

In the case of detection of an oral mucosal lesion, persistent for more than two weeks after local irritants removal and/or with clinical characteristics compatible with a PMOL, it is appropriate to carry out an immediate biopsy of the lesion. The use of diagnostic visual aids, such as toluidine blue staining and/or tissue autofluorescence visual assessment, can improve the results of the visual clinical examination and serve as a guide for the bioptic tissue sampling.

Dr. Silvio Abati, M.D., D.M.D
Professor of Oral Diseases
Medical School and Dental School
University Vita-Salute San Raffaele - Milano



Recommended Readings

1. Scully C, Bagan J. Oral squamous cell carcinoma: overview of current understanding of aetiopathogenesis and clinical implications. *Oral Dis* 2009; 15:388–399.
2. Neville BW, Day TA. Oral cancer and precancerous lesions. *CA Cancer J Clin* 2002; 52:195–215.
3. Warnakulasuriya S, Johnson NW, van der Waal I. Nomenclature and classification of potentially malignant disorders of the oral mucosa. *J Oral Pathol Med* 2007; 36:575–580.
4. Villa A, Villa C, Abati S. Oral cancer and oral erythroplakia: an update and implication for clinicians. *Aust Dent J*. 2011 Sep;56(3):253-6.
5. Tiwari L, Kujan O, Farah CS. Optical fluorescence imaging in oral cancer and potentially malignant disorders: A systematic review. *Oral Dis*. 2019; 00:1–20.

